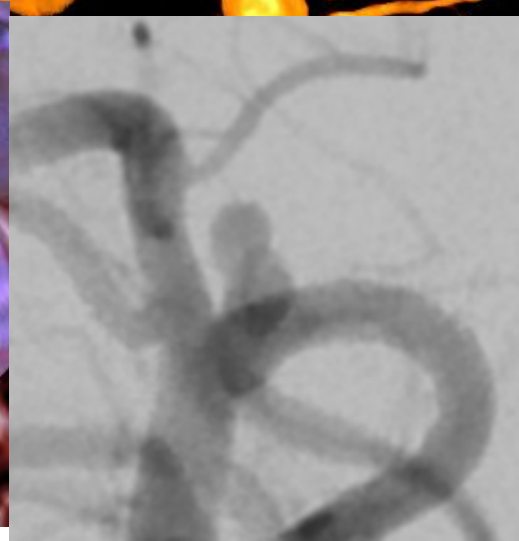
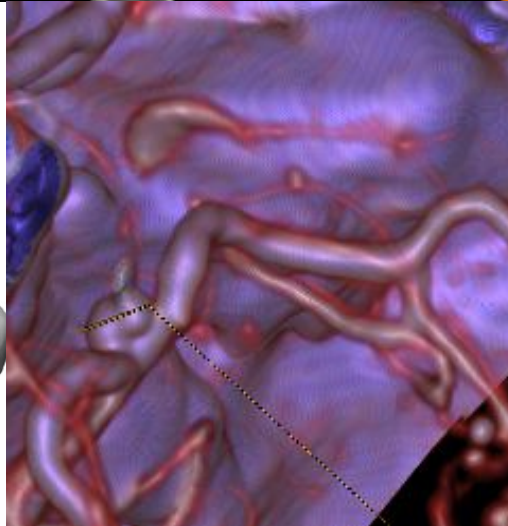
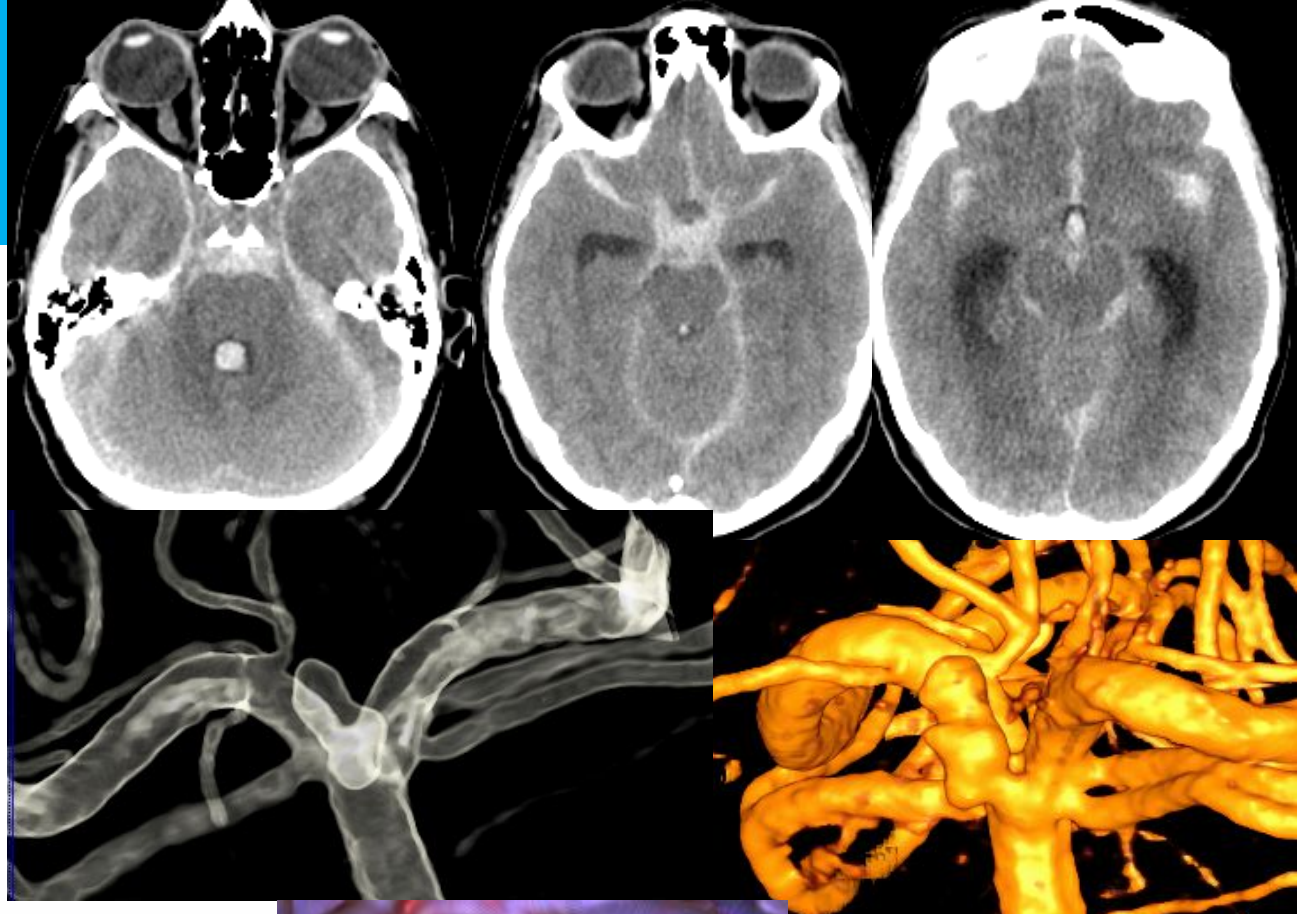
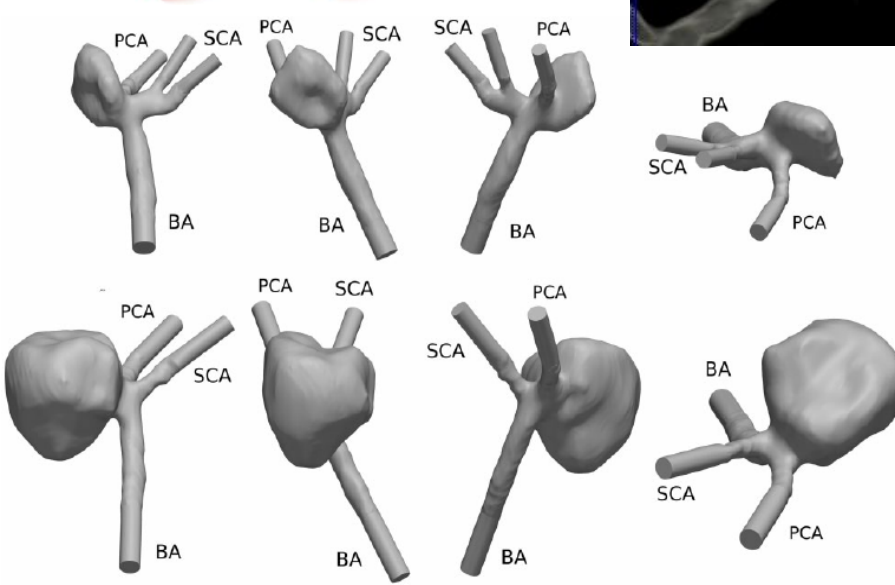
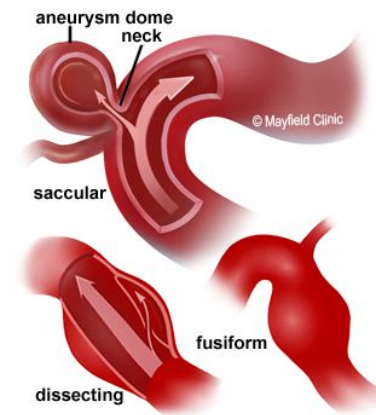


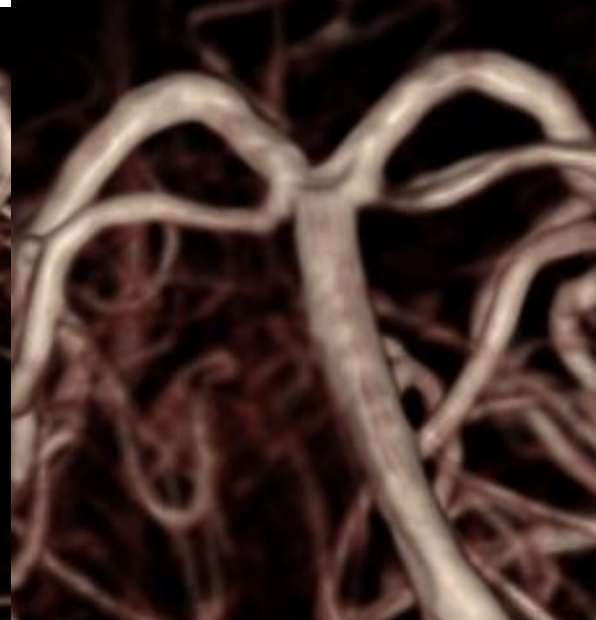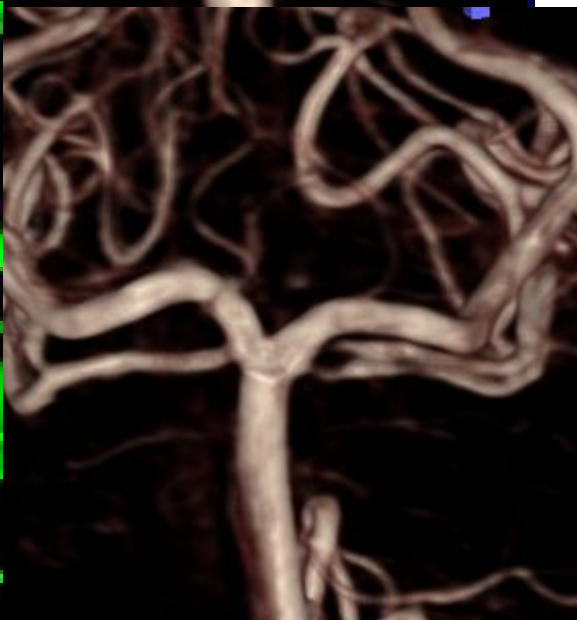
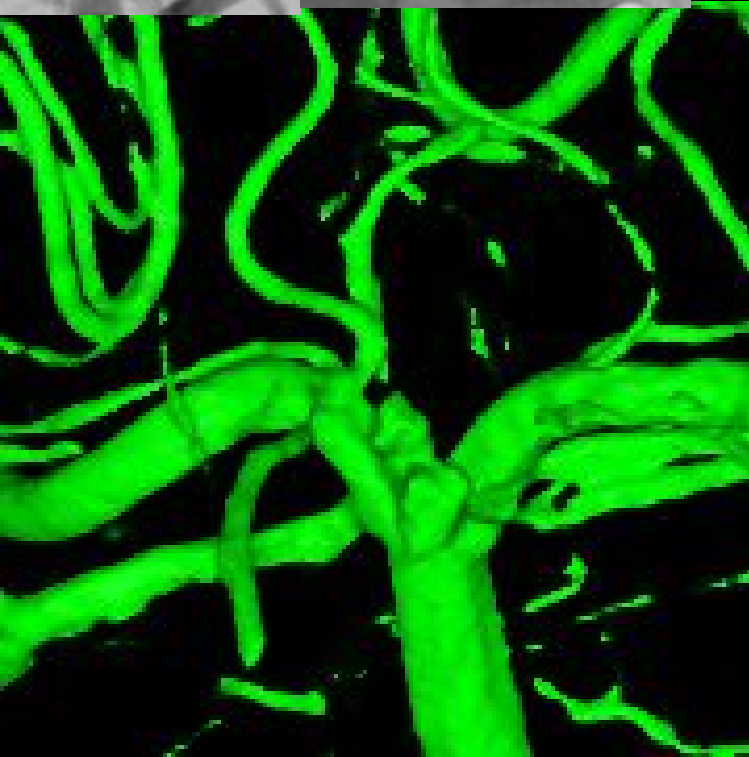
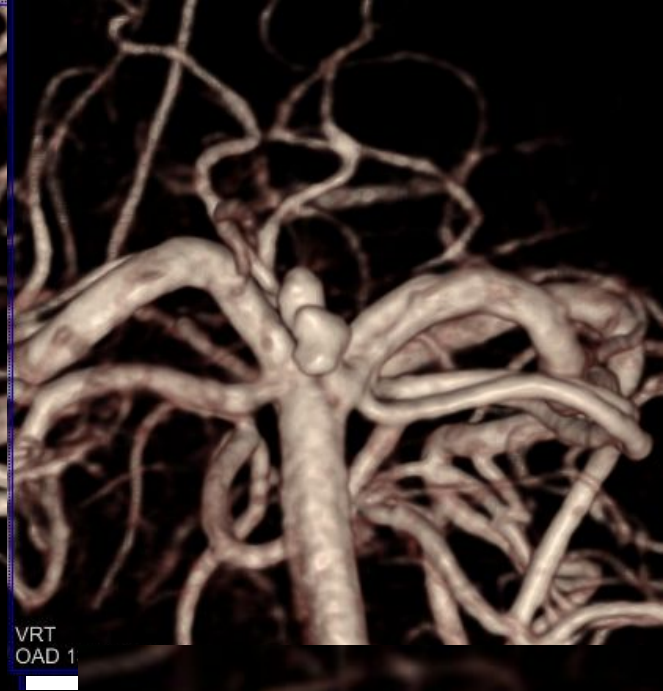
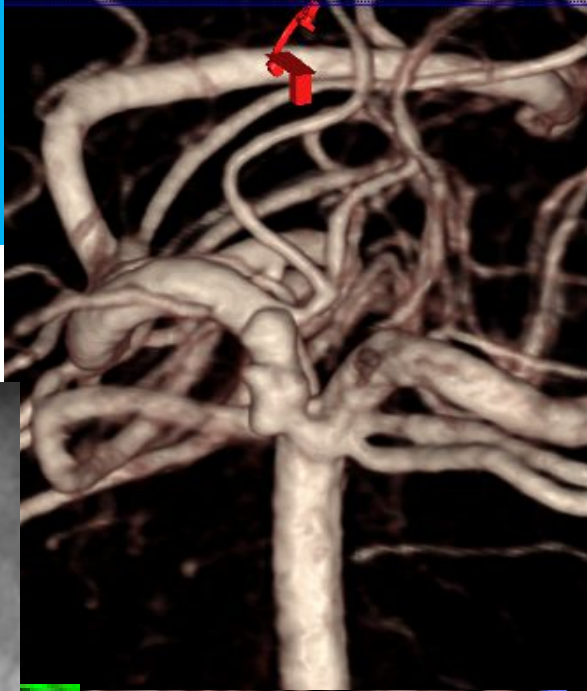
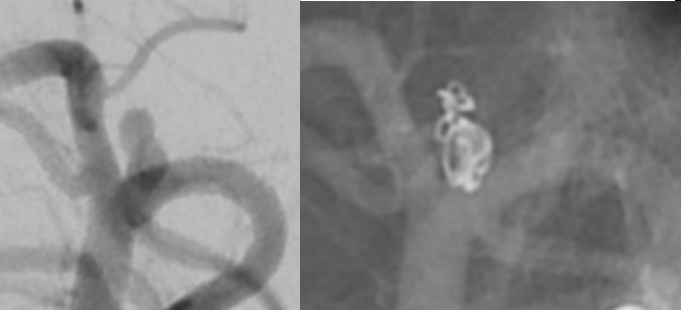
Aneurisma sacular roto del top basilar.

Cefalea.
HSA Grado IV.
Aneurisma sacular roto bilobulado del top basilar.
Tratamiento con coils.

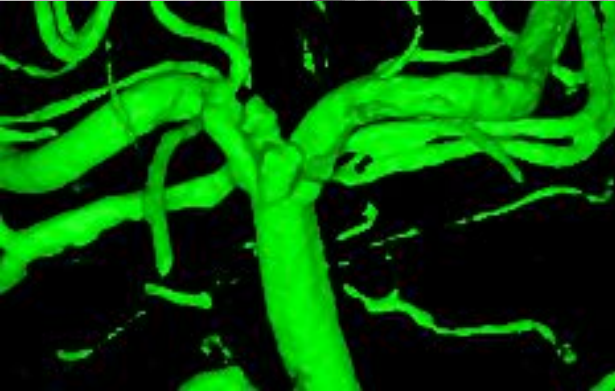
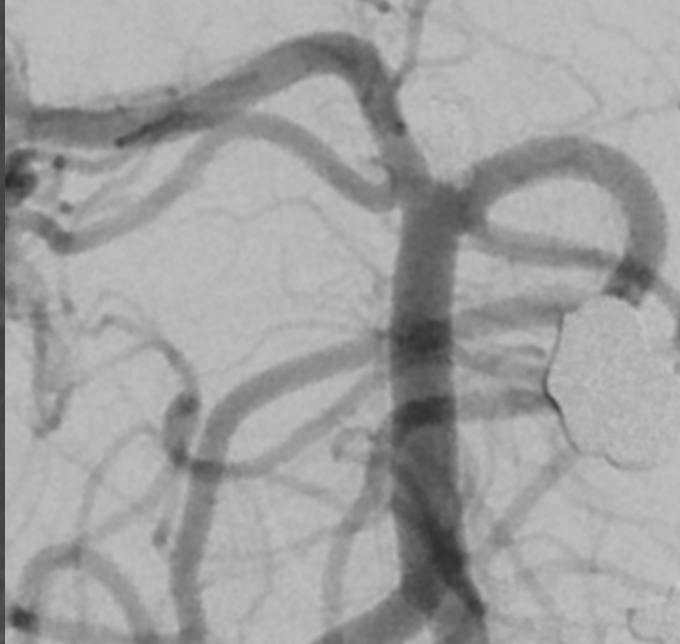
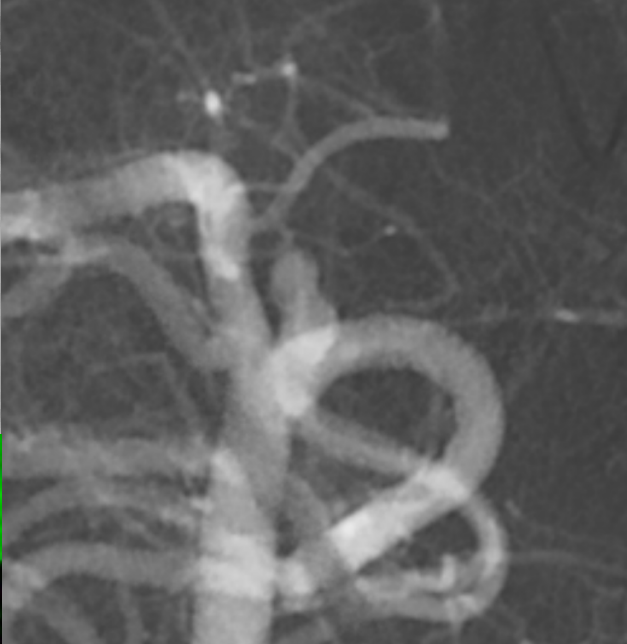
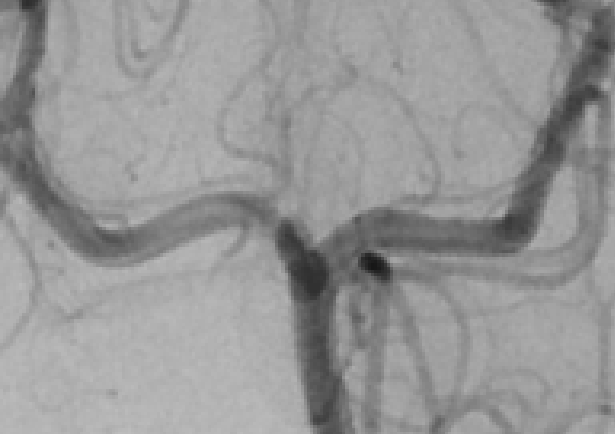
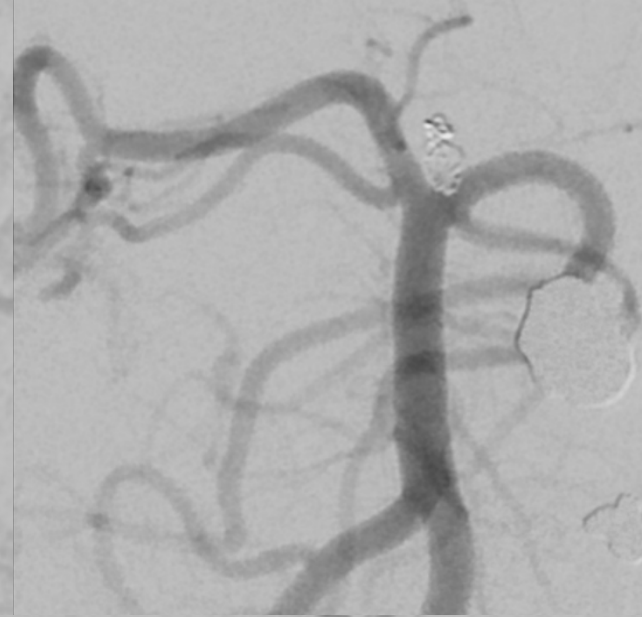
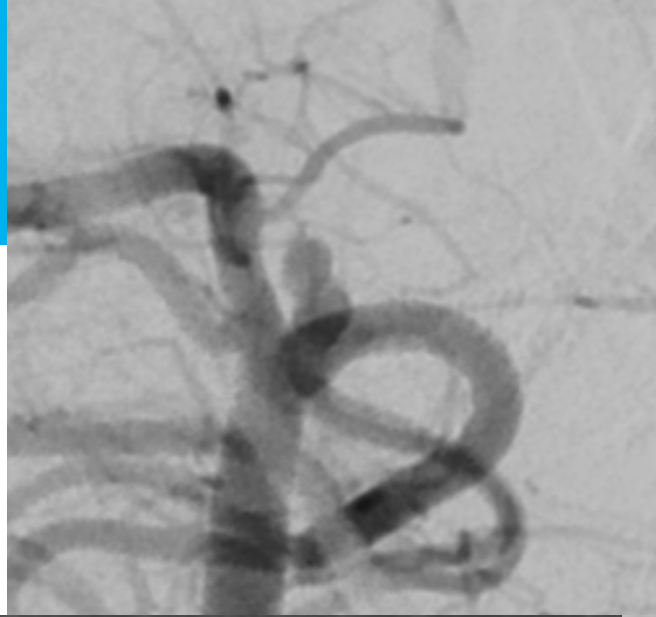
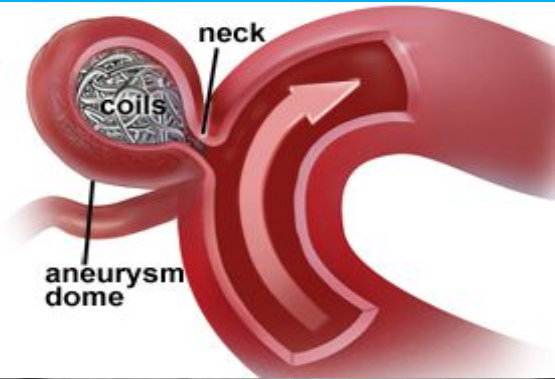


Aneurisma sacular roto del top basilar.

Aneurisma sacular de la arteria basilar distal embolizado con coils Gdc con resultado endovascular satisfactorio.



Aneurisma sacular roto del top basilar.



Aneurisma sacular de la arteria basilar distal embolizado con coils Gdc y técnica de balón asistida (transform 4 mm x 20 mm) con resultado endovascular satisfactorio.

Aneurisma sacular roto del top basilar.

Tratamiento endovascular para aneurismas de la arteria basilar distal roto y no roto.

